

Clinical Insights in Diagnosing Glaucoma

Murray Fingeret, OD, FAAO
 Chief, Optometry Section
 VA New York Harbor
 Brooklyn/St. Albans Campus
 Clinical Professor, SUNY College of Optometry
 murrayf@optonline.net

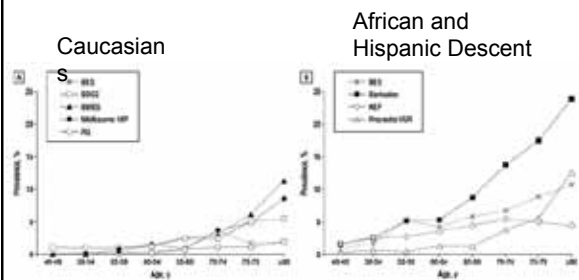
Clinical Insights Diagnosis of Glaucoma

- Tests
 - History
 - IOP
 - Gonioscopy
 - Pachymetry
 - Dilated optic nerve assessment- stereo
 - Imaging
 - HRT, GDx, OCT
 - Perimetry- Standard Automated Perimetry (SAP)
 - Selective perimetric tests
 - FDT, SITA SWAP

What are the Risks Associated with the Development of Glaucoma?

- Age
- Race
 - African descent
 - Hispanics
 - Asian for narrow angle
- Family history
- History cardiovascular disease & Reduced blood press
- Prior use of steroids
- Medications
 - Systemic beta blockers
 - Diuretics
- Perfusion pressure
 - Blood pressure minus IOP

Glaucoma Prevalence: Increasing with Age



Goldmann Applanation Tonometry

- Goldmann applanation tonometry assumes central corneal thickness (CCT) of 500 μm
- GAT over- or under-estimates IOP by as much as 5 mmHg for every 70 μm of CCT difference from $\sim 520\mu\text{m}$



Pachymetry is Part of the Ocular Examination Whenever Glaucoma is Suspected

Central Corneal Thickness and the Diagnosis of Glaucoma

- Re-classification on basis of correction factors
 - 44% of Normal Tension Glaucoma become POAG
 - 35% of Ocular Hypertension become normal

CCT and risk of glaucoma

- Is the increased risk of glaucoma with a thin cornea a result of
 - IOP measurement error?
 - Greater susceptibility?
 - do corneal biomechanical properties reflect scleral/lamina biomechanical properties?

Should You Use the Pachymeter To Screen for Glaucoma?

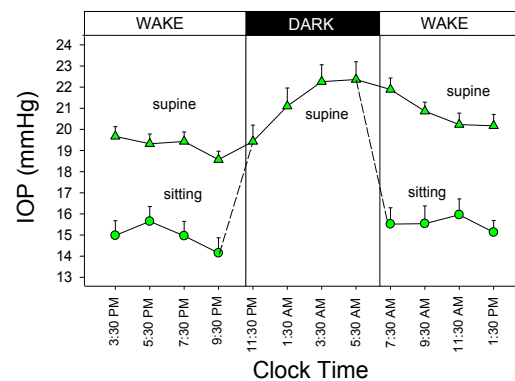
Should you do the Test on Everyone Presenting to your Office, Not Just Suspects or Those with Glaucoma?

Should IOP be adjusted for Central Corneal Thickness?

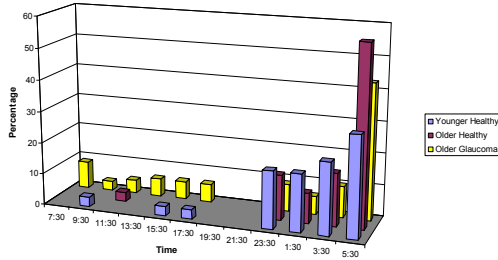
Is there a purpose for the conversion charts that come with pachymeters?

What Should One Do When a Person Has Glaucoma and the IOP Never Appears to be Elevated?

24-hour IOP pattern, young adults (18-25 years, N=21)



Distribution (%) of 24-hour peak IOP (habitual body positions)



Key Factors for Gonioscopy

- Good anesthesia
- Dark room
- Start with 1mm, narrow beam of light
 - Keep beam away from pupil
- Patient's maintains primary gaze
- Minimize lens tilt
 - Only minor movements permitted to see over convexity of iris
 - Otherwise narrow open will appear open

Key Factors for Gonioscopy

- Use high magnification
- Assess whether iris is in contact with TM
- If not, estimate geometric angle b/w TM and adjacent peripheral area of iris
- Describe level of most anterior point of contact b/w iris and cornea-scleral coat
- Once gonio is completed 360°, repeat with increased illumination and indentation

Key Factors for Gonioscopy

- To understand if angle is narrow but open,
 - For Goldmann style lenses, instruct patient to look toward mirror while pressing on rim of lens overlying mirror
 - Indents central cornea
- Describe the level of insertion of iris as well as height and circumference of peripheral anterior synechia

Why Document?

- Evidence suggests disc documentation is poor
- Glaucoma staging
- Disc size determination
- Assessment of quantitative and non-quantitative features
- Global risk assessment
- Detection of progression

What is the First Optic Nerve Instrument I Should Buy?

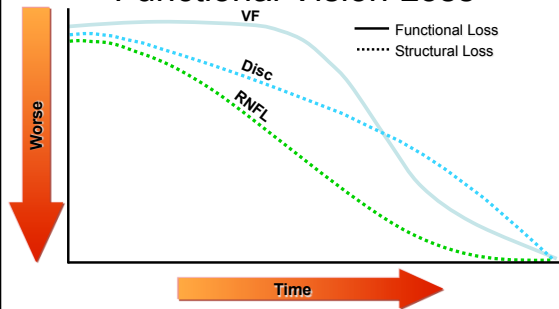
A Digital Fundus Camera

Standard of Care is For Some Form of Documentation When Glaucoma is Presented or Suspected
 May be done with Photography or Imaging

Do We Need Imaging?

- Will Imaging Allow Earlier Diagnosis?
 - More cases detected based upon structural evaluation of the optic nerve or NFL using imaging instrumentation?
- Is IMAGING the STANDARD of CARE?
 - No, documentation is
 - Imaging is very useful but not required AT THIS TIME

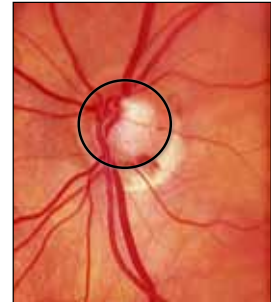
Structural Damage May Precede Functional Vision Loss



Weinreb. Presented at: The AGS Subspecialty Day Lecture: Getting Closer to Glaucomatous Optic Neuropathy, October 19, 2002; Orlando, Fla.

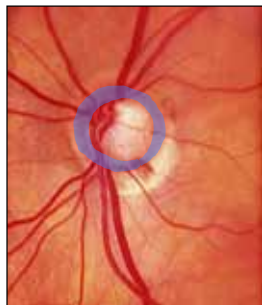Five Rules for Assessment of the Optic Disc in Glaucoma

- 1 Observe the scleral Ring to identify the limits of the optic disc and its size



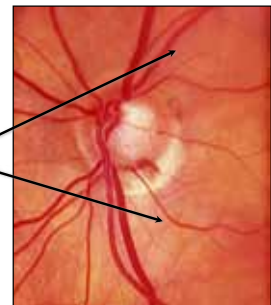Five Rules for Assessment of the Optic Disc in Glaucoma

- 1 Observe the scleral Ring to identify the limits of the optic disc and its size
- 2 Identify the size of the Rim



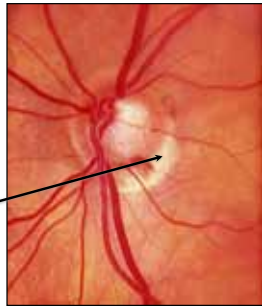
Five Rules for Assessment of the Optic Disc in Glaucoma

- 1 Observe the scleral Ring to identify the limits of the optic disc and its size
- 2 Identify the size of the Rim
- 3 Examine the Retinal nerve fiber layer



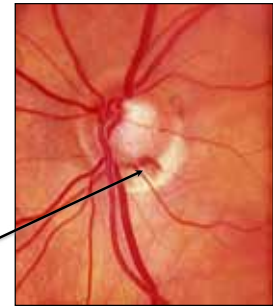
Five Rules for Assessment of the Optic Disc in Glaucoma

- 1 Observe the scleral Ring to identify the limits of the optic disc and its size
- 2 Identify the size of the Rim
- 3 Examine the Retinal nerve fiber layer
- 4 Examine the Region of parapapillary atrophy



Five Rules for Assessment of the Optic Disc in Glaucoma

- 1 Observe the scleral Ring to identify the limits of the optic disc and its size
- 2 Identify the size of the Rim
- 3 Examine the Retinal nerve fiber layer
- 4 Examine the Region of parapapillary atrophy
- 5 Look for Retinal and optic disc hemorrhages

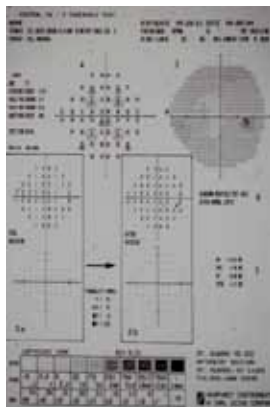


Structural Assessment in Glaucoma

- The Optic Nerve Head
- The Nerve Fibre Layer Retinal Thickness

Six Steps in Analyzing the Single Field Printout

- Reliability Indices
- Gray Scale
- Raw Data
- Total/Pattern Deviation Printouts
 - Compare between the two
 - Explain any differences
- Global Indices
- Glaucoma Hemifield Test



False Positives may be the Most Important Reliability Indicator

Second Best is Whether the Blind Spot was Plotted
Is there a 0?

Unreliable Visual Field

- Excessive Fixation Losses
- High False Positives
- Borderline False Negatives
- White Scotomas
- GHT-Abnormally High Sensitivity

False Negatives are Not a Good Indicator of Unreliability

The Learning Curve is Real Glaucomatous Visual Fields are Extremely Variable

Need to confirm change and
confirm again

New Tools for Diagnosing Glaucoma

- Structure vs. Function
- Goal is to Detect Damage Very Early
- What is Their Role?
- What do you do when imaging test is positive is everything else is negative
 - Does the imaging test drive the diagnosis?

Selective Perimetric Tests FDT Matrix, HEP and SITA SWAP

Frequency Doubling Perimetry

- Low spatial frequency (<1 cycle per degree) and high temporal frequency (25Hz) grating
 - undergoes counter phase flicker
- 10° target size
 - large target
 - reduced fluctuation
 - reduced variability across field
 - scotomas once identified tend to be consistent
- Contrast varied in step wise fashion until detected

Short Wavelength Automated Perimetry (SWAP)

- Also called Blue-Yellow perimetry
- Detects early damage several years before present on conventional perimetry
- Now available in SITA Mode
 - SITA SWAP